European Journal of Neuroscience, Vol. 23, pp. 659–666, 2006 doi:10.1111/j.1460-9568.2006.04616.x

LRRK2 is expressed in areas affected by Parkinson's disease in the adult mouse brain

Javier Simón-Sánchez,[1] Vicente Herranz-Pérez,[1] Francisco Olucha-Bordonau[2] and Jordi Pérez-Tur[1]
[1]Unitat de Genètica Molecular, Departament de Genòmica i Proteòmica, Institut de Biomedicina de València-CSIC, C/Jaume Roig, 11, E46010 València, Spain
[2]Departament d'Anatomia i Embriologia Humana, Facultat de Medicina, Universitat de València-Estudi General, València, Spain

Keywords: dardarin, expression, mousebrain, Parkinson's disease

Abstract

The leucine-rich repeat kinase 2 (*LRRK2*) gene was recently found to have multiple mutations that are causative for autosomal dominant inherited Parkinson's disease (PD). Previously, we used Northern blot analysis to show that this gene was expressed in the cerebellum, cerebral cortex, medulla, spinal cord, occipital pole, frontal lobe, temporal lobe and caudate putamen. However, a more comprehensive map of *LRRK2* mRNA localization in the central nervous system is still lacking. In this study we have mapped the distribution of the mRNA encoding for *LRRK2* using nonradioactive *in situ* hybridization. We detected a moderate expression of this PD-related gene throughout the adult B2B6 mouse brain. A stronger hybridization signal was observed in deep cerebral cortex layers, superficial cingulate cortex layers, the piriform cortex, hippocampal formation, caudate putamen, substantia nigra, the basolateral and basomedial anterior amygdala nuclei, reticular thalamic nucleus and also in the cerebellar granular cell layer. Given that *LRRK2* mRNA is highly enriched in motor systems and also is expressed in other systems, we may conclude that mutations in *LRRK2* may affect several motor and nonmotor structures that may play an important role in the development of PD.

Introduction

Parkinson's disease (PD) is the second most common neurodegenerative disorder, affecting 2% of people over 65 years of age. Although the majority of PD cases are sporadic, a small percentage is caused solely by mutations in several recently identified genes. Despite their low frequency, genes that are causative for PD are extremely important as they can highlight the mechanisms and pathways leading to the onset of the disease, and foster the identification of new forms of therapeutic treatment.

The familial variant of PD can be divided into autosomal dominant and autosomal recessive forms. The currently identified autosomal dominant forms of PD can be due to mutations in the genes encoding α-synuclein (*SNCA*, PARK1), ubiquitin carboxyl-terminal esterase L1 (*UCH-L1*, PARK5) or dardarin (*LRRK2*, PARK8); while the autosomal recessive variants are caused by mutations in the genes encoding Parkin (*PRKN*, PARK2), DJ-1 (*DJ-1*, PARK7) and PTEN inducible kinase 1 (*PINK-1*, PARK6).

Recently our group identified four families from the Basque region in Spain with the autosomal dominant PD (Paisan-Ruiz *et al*., 2005). A multipoint linkage analysis showed us that these four families were linked to the PARK8 *locus* (12p11.2q13.1) described by Funayama *et al*. (2002). By means of systematic sequence analysis, we identified segregating mutations in all four Basque families within a 9 kb predicted transcript (Paisan-Ruiz *et al*., 2004). The approved symbol for the gene, *LRRK2*, is due to the presence of both the leucine-rich and MAPKKK domains in the protein. The protein is known as dardarin, a word that originated from the Basque word *dardara* meaning 'tremor'. While the expression patterns of previously identified genes such as *SNCA*, *PRKN*, *UCHL-1* and *DJ-1* have been reported, those for *LRRK2* are yet to be investigated.

An *in silico* analysis of dardarin using the SMART website (http://smart.embl-heidelberg.de) suggested that dardarin is a complex protein belonging to the ROCO kinases superfamily (Bosgraaf & Van Haastert, 2003). Proteins belonging to the ROCO superfamily stand out because of the existence of two conserved domains: a Roc (Ras on complex proteins) domain and a COR (C-terminal of Roc) domain. Ras-like domains are often involved in rearrangements of actin cytoskeleton, and they also play an important role in Ras-mediated cell transformation, cytokinesis, focal adhesion formation and MAPK pathway stimulation. In addition to these, a further three domains are also found in dardarin; leucine rich repeats (LRR), a tyrosine catalytic domain and a WD40 domain.

Our analysis of gene expression by Northern blot previously indicated that *LRRK2* gene is expressed in the cerebellum, cerebral cortex, medulla, spinal cord, occipital pole, frontal lobe, temporal lobe and putamen (Paisan-Ruiz *et al*., 2004). However, a complete map of *LRRK2* mRNA localization in the central nervous system is still lacking. The objective of this study is to provide a complete atlas of *LRRK2* mRNA distribution in the adult mouse brain.

Materials and methods

In situ *hybridization*

This work is based on five B2B6 adult male mice. All animal manipulations were approved by the Animal Care and Ethics Committee of the CSIC and the School of Medicine of the University of Valencia. Animals were ether-anaesthetized and decapitated. Brains

Correspondence: Dr Jordi Pérez-Tur, as above.
E-mail: jpereztur@ibv.csic.es

Received 31 October 2005, revised 29 November 2005, accepted 8 December 2005

© The Authors (2006). Journal Compilation © Federation of European Neuroscience Societies and Blackwell Publishing Ltd

were quickly removed and immersed overnight in a fixative containing 4% paraformaldehyde in 0.1 M pH 7.4 phosphate buffered saline-0.01% diethyl pyrocarbonate (PBS-DEPC). After immersing the fixed brains in gelatine glutaraldehyde for 30–60 min, a coronal serial of 50-μm-thick coronal sections were prepared using a vibratome (VT1000M, Leica).

Chromogenic *in situ* hybridization was performed as described elsewhere. Briefly, coronal sections of adult B2B6 mice were dehydrated and then rehydrated in a graded methanol series. Next, they were treated with proteinase K and fixed in paraformaldehyde. After this treatment, the sections were prehybridized for 2–16 h at 50 °C prior to incubating them for 3 h at 57 °C with the digoxigenin-labelled probe. After removal of nonspecific binding by sequential washes of decreasing concentrations of SSC, the presence of the *LRRK2* mRNA was revealed using a HRP-conjugated digoxigenin antibody and a chromogenic reaction using nitroblue tetrazolium chloride and 5-bromo-4-chloro-3-indolyl phosphate (all reagents from Roche Diagnostics). All reagents and materials were treated as necessary to ensure the absence of RNase contamination.

Probe synthesis

Two *in situ* hybridization probes were synthesized by means of PCR amplification. The probes were amplified from a mouse cDNA library (Invitrogen) that recognized a fragment of the *LRRK2* gene from codon 1004 to codon 1172 (probe 1) or a fragment from codon 2013 to codon 2171 (probe 2). The oligonucleotides used for this amplification were the following:

LRRK2-PROBE1-F 5′-ATCATCTAGAGTTGCCTCAGTAGCCACC-3′
LRRK2-PROBE1-R 5′-ATCAGTCGACAAGGTAAGGCAGGCATTG-3′
LRRK2-PROBE2-F 5′-TACGTCTAGAGCGAAGATTGCGGACTAC-3′
LRRK2-PROBE2-R 5′-CACAGATATCCCAACCAGAGAGTCGCAC-3′

The PCR conditions used were two minutes at 95 °C followed by 35 cycles of 30 s at 95 °C, 30 s at 58 °C and 1 min at 72 °C. After cycling, a 10-min step at 72 °C was performed. For this amplification *Pfu turbo* polymerase was used as per manufacturer's instructions (Stratagen). The amplified product was resolved on a 2% agarose-TBE gel, extracted using the Minilute Gel extraction kit (Qiagen) and cloned into the *Xba*I-*Sal*I sites of the pBluescript KS-II^{-} vector (Stratagene) using the Rapid ligation kit (Roche). The probes were synthesized by linearizing the construct with either *Xba*I (antisense probe) or *Sal*I (sense probe) followed by *in vitro* transcription with digoxigenin labelled nucleotides using an RNA oligonucleotide synthesis kit (Roche). To avoid secondary structure formation, RNA synthesized probes were diluted with 50% formamide. Both probes yielded equivalent results, only those for probe 1 are shown.

Relative regional expression

To determine the level of the *LRRK2* expression in different areas of the brain we performed several experiments with different development times (from 2 to 16 h). The level of expression was then correlated with the time needed to obtain clear staining in each of the areas shown in Table 1. When a clear staining was observed in a particular area during the first 2 h of developing, it was assigned a +++ mark, those areas that were clearly stained after 9 h of chromogenic reaction were assigned as ++ whereas those stained after 16 h of staining were designated with +. Those which revealed no staining after 16 h were considered as not being able to express *LRRK2* or at least their level of expression was not detectable with this particular technique.

TABLE 1. Relative levels of expression of *LRRK2* in adult mouse brain

Brain area	*LRRK2* mRNA
Telencephalon	
Cerebral cortex	++
Olfactory tubercle	++
Piriform cortex	+++
Claustrum	+
Hippocampal formation	
Ammon's horn	+++
Dentate gyrus	+++
Septal area	
Tenia tecta	++
Vertical medial septal nucleus	+
Horizontal medial septal nucleus	++
Lateral septal nucleus	+
Septohippocampal nucleus	++
Nucleus Triangularis septalis	–
Amygdala and extended amygdala	
Amygdaloid intramedullary grey	+++
Amygdalopiriform transition area	++
Amygdalostriatal transition area	+++
Basolateral amygdaloid nucleus	+++
Basomedial amygdaloid nucleus	+++
Central amygdaloid nucleus	+
Medial amygdaloid nucleus	+++
Lateral amygdaloid nucleus	++
Nucleus of the lateral olfactory tract	–
Cortical amygdala	–
Bed nucleus of the stria terminalis	++
Basal ganglia	
Globus pallidus	–
Caudate putamen	+++
Nucleus accumbens	–
Diencephalon	
Thalamus	
Anterodorsal nucleus	++
Reticular nucleus	++
Parafascicular nucleus	+
Mediodorsal nucleus	++
Centrolateral nucleus	+
Paraventricular nucleus	+++
Geniculate	++
Habenular complex	
Medial nucleus	+++
Lateral nucleus	–
Subthalamus	++
Zona incerta	++
Hypothalamus	
Preoptic nuclei	–
Posterior area	+
Dorsal area	+
Ventrolateral nucleus	+
Ventromedial nucleus	++
Dorsomedial nucleus	++
Brainstem	
Pretectum	+
Ventral tegmental area	+
Red nucleus	++
Nucleus of Darkschewitsch	++
Ventral tegmental area	+
Periaqueductal gray	++
Median raphe	++
Dorsal raphe	++
Dorsal tegmental nuclei	–
Pontine nuclei	++
Superior colliculus	++
Inferior colliculus	+
Substantia nigra	
Pars compacta	+++
Pars reticulata	–
Cerebellum	
Cerebellar nuclei	–
Cortex	
Purkinge cell layer	–
Granule cell layer	++

© The Authors (2006). Journal Compilation © Federation of European Neuroscience Societies and Blackwell Publishing Ltd

Results

We studied the *LRRK2* mRNA expression in adult mice brains through *in situ* hybridization analysis using digoxigenin-labelled RNA probes. We first confirmed the specificity of the probe by comparing the staining pattern of the antisense probe with that of the sense probe. The antisense probe showed specific signal patterns, whereas no signal was observed with the sense probe. This difference between both probes indicates that the antisense probe can specifically hybridize with its corresponding transcript (Fig. 1).

As a result we found that *LRRK2* mRNA was expressed throughout the mouse brain. As summarized in Table 1, signal intensities varied from undetected (–), faint (+), moderate (++) and strong (+++). A detailed description of the most relevant findings organized into brain areas is as follows.

Telencephalon

Different *LRRK2* mRNA expression patterns were observed in different cortical areas. In some areas, *LRRK2* was expressed throughout the six cortical areas and the signal intensity depended on the cell density in each layer. This was the case of cingular-frontal (Fig. 2A), temporal (Fig. 2D) or occipital and the medial prefrontal cortex. In other areas, *LRRK2* was absent or in disperse neurons in specific cortical layers. In the hindlimb area of the cortex (Fig. 2B) and in the parietal cortex (Fig. 2C), labelling was specifically scattered into the layers II/III and in layer V.

Within the septal area, *LRRK2* mRNA was not expressed in the nucleus triangularis septalis and was weakly expressed in the dorsal, ventral and intermediate parts of the lateral septal nucleus. However, a strong signal was observed in the horizontal limb of the medial septal nucleus, and a less but consistent labelling appeared in its vertical division dorsal tenia tecta. Furthermore, this gene was also highly expressed in the adjacent septohippocampal nuclei (Fig. 3A).

Within the hippocampus, *LRRK2* mRNA was abundantly expressed in the pyramidal cell layer of Ammon's horn (CA1, CA2 and CA3) as well as in the granular cell layer of the dentate gyrus (Fig. 3B). A strong expression was also observed in disperse neurons either located in the molecular or in the radiatum-oriens layers. Strong labelling was also observed in the hilar region of the dentate gyrus.

LRRK2 mRNA was strongly expressed in almost every part of the amygdala except for the cortical-superficial area (Fig. 3C). Thus, it was strongly expressed in the amygdaloid intercalary grey area, the amygdalostriatal transition area, and it was moderately expressed in the amygdalopiriform transition area. With regard to the basal amygdaloid nucleus, a very strong *LRRK2* expression was observed in the lateral, basomedial, basolateral and posterior basal divisions (Fig. 3D). A strong *LRRK2* expression was noted in the medial amygdaloid nucleus in both the posterodorsal and posteroventral parts. *LRRK2* expression was also detected in the intra-amygdaloid division of the bed nucleus of the stria terminalis close to the posterodorsal area of the medial amygdaloid nucleus and also in the central amygdala. The cortical nucleus, located proximally to the medial amygdaloid nucleus, also expresses *LRRK2* mRNA in both the posterolateral and posteromedial parts. No signal was seen in the nucleus of the lateral olfactory tract or in the cortical amygdala (Fig. 3C).

LRRK2 mRNA expression was high in the most superficial layers of the piriform cortex (Fig. 3E). The olfactory tubercule and the islands of Calleja are located close to the piriform cortex, which also showed strong *LRRK2* expression (Fig. 3F).

Within the basal ganglia area, *LRRK2* mRNA was detected throughout the striatum, where no patchy differences were observed that can indicate a possible differential reaction between striosome and matrix. Interestingly, the globus pallidus was nearly devoid of any *LRRK2* expression (Fig. 4A).

Diencephalon

With the exceptions of the paraventricular thalamic nucleus (Fig. 4B) and the reticular nucleus (Fig. 4C), which strongly expresses *LRRK2* mRNA, all the nuclei within the thalamus moderately expressed this gene (Fig. 4C). Some labelled cells were observed in both the medial and lateral geniculate nuclei.

A strong *LRRK2* mRNA expression was also observed in the medial habenular nucleus. However, only a very faint expression could be

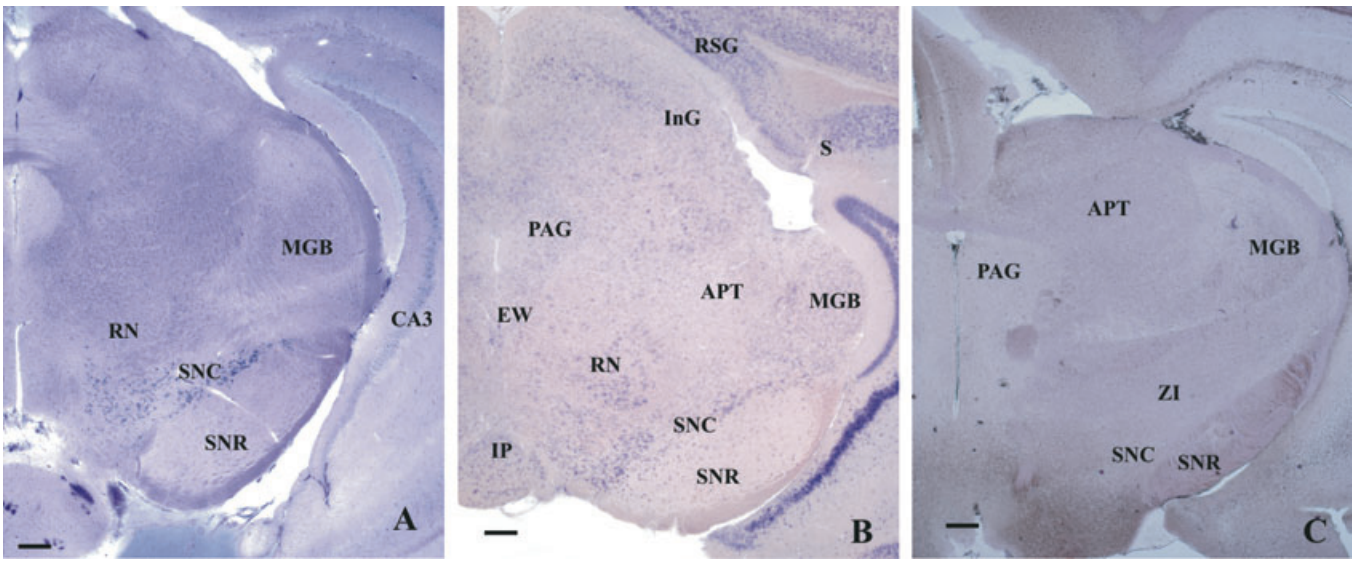

FIG. 1. *LRRK2* mRNA expression in the mouse brain. Note that the antisense probe (A) shows a specific hybridization pattern and that the sense probe (C) show no hybridization signal. The hybridization pattern observed after 2 h of developing time is shown in A. In (A) and (B) note the strong reaction in the substantia nigra pars compacta and in some midbrain nuclei, including the interpeduncular and red nuclei as well as the periaqueductal gray and superios colliculus. Definitions of the abbreviations used in Figs 1–4 are included in the Abbreviations list. Calibration bars, 200 μm.

© The Authors (2006). Journal Compilation © Federation of European Neuroscience Societies and Blackwell Publishing Ltd

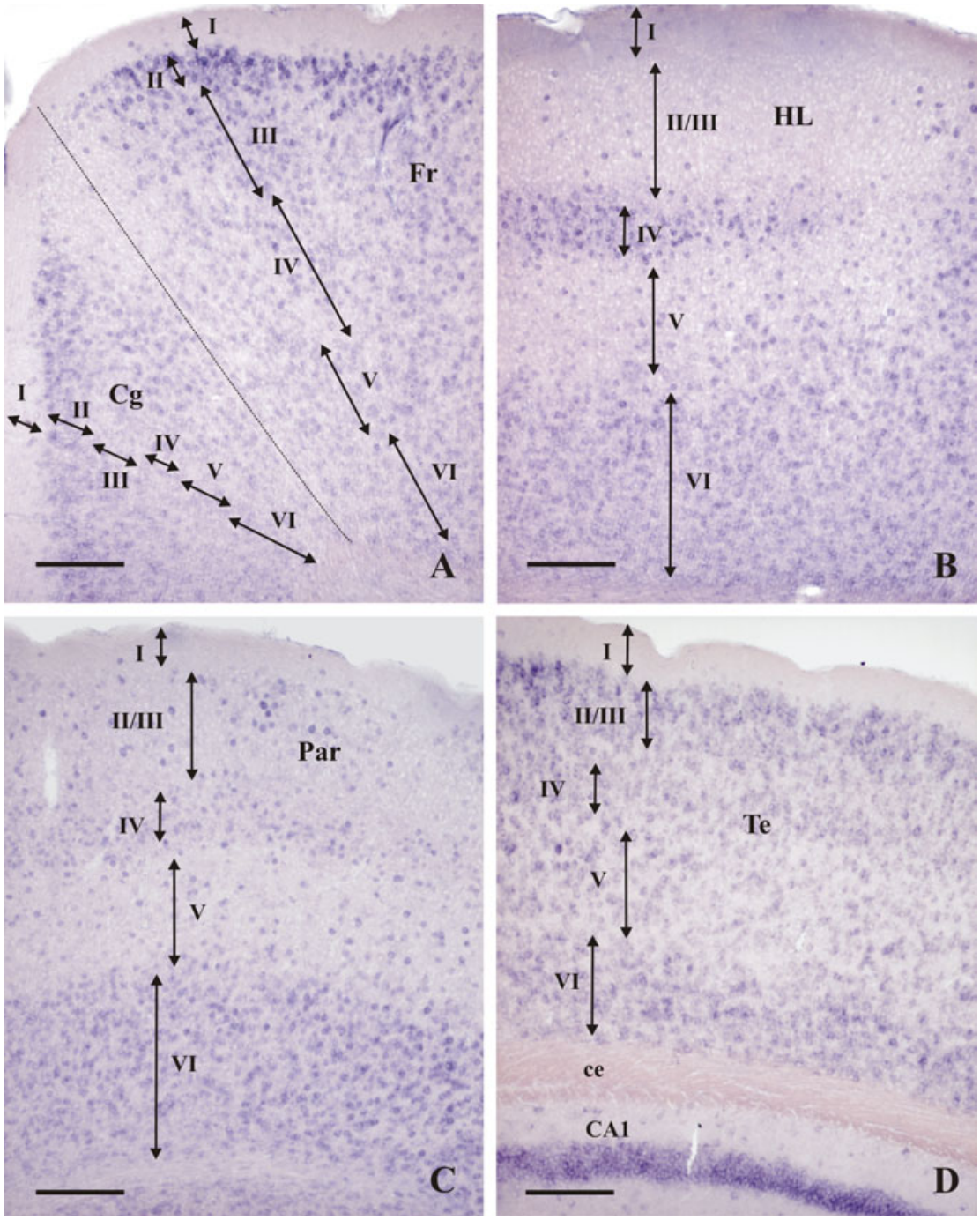

FIG. 2. *LRRK2* mRNA expression in different cortical areas (A) cingular/frontal cortical areas (B) hindlimb cortical area (C) parietal cortex, and (D) temporal cortex. Note that in both the hindlimb and parietal cortices, layers II/III and V showed scattered labelling. A long (12 h) chromogenic reaction was performed in all these cases. Calibration bars, 200 μm.

seen in the lateral nucleus (Fig. 4B). The zona incerta also contained strongly labelled neurons (Fig. 3C).

With regard to the hypothalamus, a *LRRK2* mRNA expression was observed in the posterior and dorsal areas, although its expression was very weak in the ventrolateral nucleus. The ventromedial hypothalamic nucleus showed a moderate-to-high expression in the dorsomedial and central parts but not in the ventrolateral one (Fig. 4D). The dorsomedial hypothalamic nucleus showed a high *LRRK2* mRNA expression in compact, ventral and dorsal parts (Fig. 4D). A scattered reaction was observed in the lateral hypothalamic area.

In addition to these above-mentioned diencephalic areas, the geniculate, zona incerta and subthalamic nucleus also expressed *LRRK2* moderately.

Brainstem

A strong *LRRK2* mRNA expression was observed in both the dorsal and ventral tiers of the substantia nigra pars compacta. In contrast, weak *LRRK2* mRNA expression was detected throughout the substantia nigra pars reticulata (Fig. 1B).

© The Authors (2006). Journal Compilation © Federation of European Neuroscience Societies and Blackwell Publishing Ltd

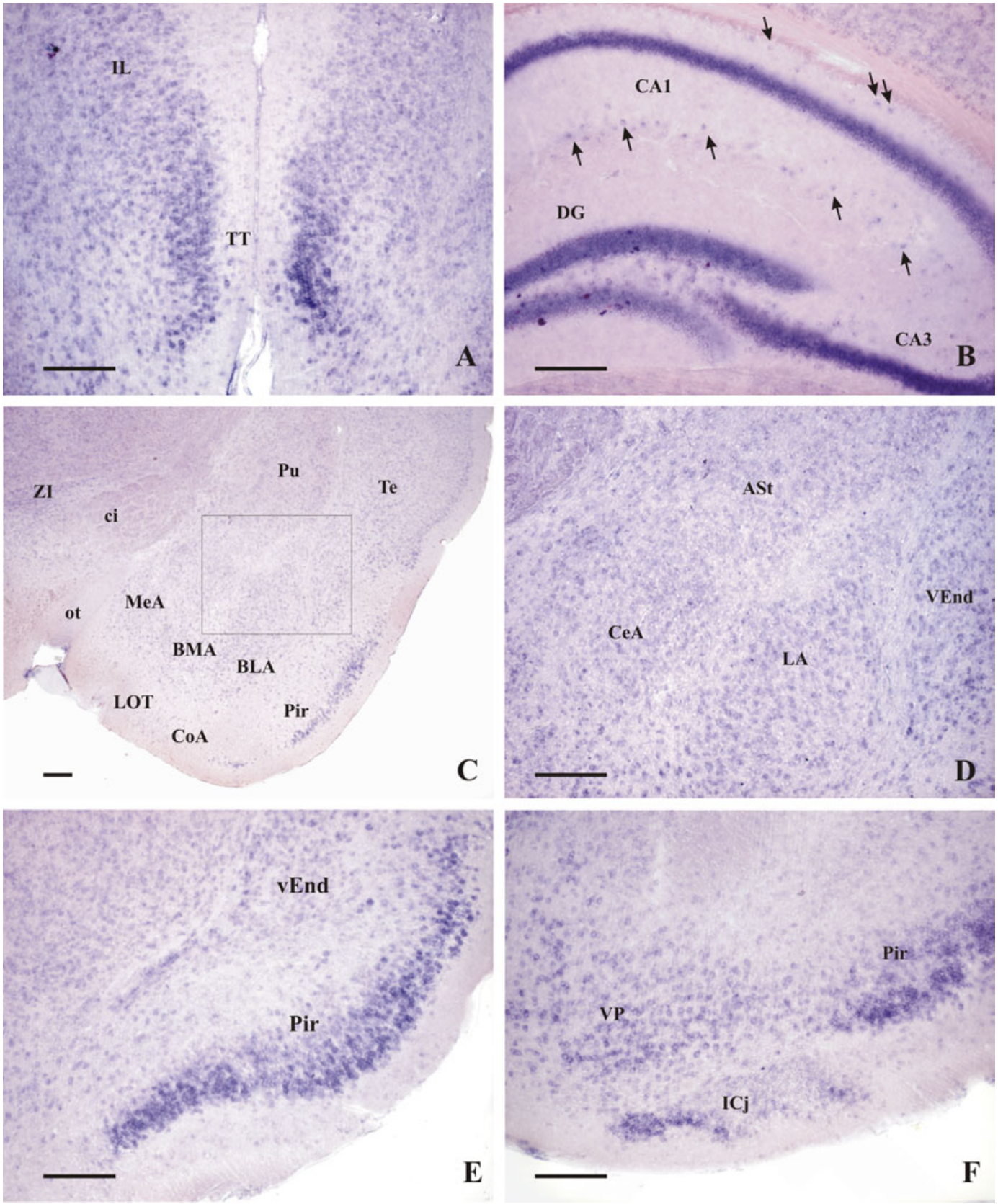

FIG. 3. *LRRK2* mRNA distribution in telencephalic areas. (A) Rostral telencephalic areas tenia tecta and infralimbic medial prefrontal cortex. (B) Hippocampus, note that the nonpyramidal neurons of the Ammons horn (arrows) as well as the hilar neurons also express *LRRK2.* (C and D) Amygdala, note the scattered labelling in cortical amygdala and the nucleus of the lateral olfactory tract the square in C as magnified in D. (E) Piriform cortex, note the strong reaction of the superficial layer. (F) Rostral ventral telencephalon showing the islands of Calleja and the ventral striatum. A long (12 h) chromogenic reaction was performed in all these cases. Calibration bars, 200 μm.

© The Authors (2006). Journal Compilation © Federation of European Neuroscience Societies and Blackwell Publishing Ltd

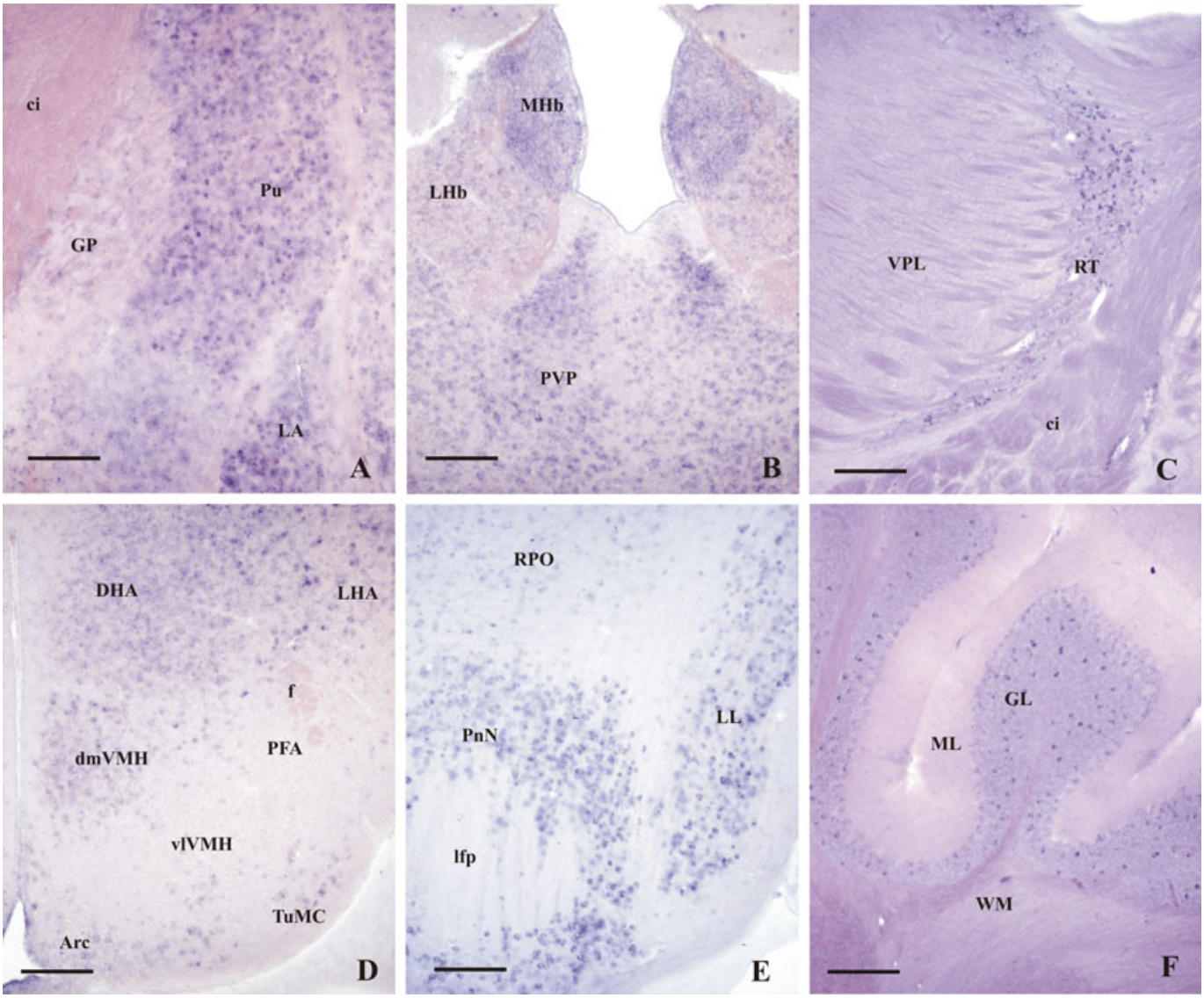

FIG. 4. *LRRK2* mRNA distribution in subcortical areas. (A) Striatum, note the strong labelling in the putamen and contrastingly, the specific scattered reaction in the globus pallidus. (B) Habenula and paraventricular thalamic nucleus, contrasting the high signal in the medial habenula, the lateral habenula only showed disperse cells. (C) Reticular thalamic nucleus in the case of a short (2 h) chromogenic reaction. (D) Ventral tuberal region of the hypothalamus, note the scattered labelling in the ventrolateral division of the ventromedial hypothalamic nucleus contrasting with the rest of the hypothalamic region and areas. (E) Ventral pons, note the strong reaction in the pontine nuclei and the ventral division of the lateral lemniscus. (F) Cerebellum, note the strong reaction in the granular layer. A long (12 h) chromogenic reaction was performed in all the cases except C. Calibration bars, 200 μm.

The ventral tegmental area and the nucleus of Darkschewitsch moderately expressed *LRRK2* mRNA. A strong reaction was observed in the intermediate grey layer of the superior colliculus (Fig. 1B) and the red nucleus. Moreover, dispersely labelled neurons also occurred in the inferior colliculus and the nuclei of the lateral lemniscus (Fig. 4E).

The periaqueductal grey also showed disperse staining (Fig. 1B). Moderate labelling was detected in the dorsal and in the median raphe nucleus. In contrast, the dorsal tegmental nuclei were almost devoid of expression.

Faint *LRRK2* mRNA expression was seen in the anterior, posterior and medial pretectal nuclei. Disperse labelling was observed along the reticular formation, whereas some cells of the pontine nuclei also expressed *LRRK2* (Fig. 4E).

Cerebellum

As seen in Fig. 4F the granular cell layer of the cerebellum exhibited a moderate *LRRK2* mRNA expression. On the other hand, neither the Purkinje cell layer nor the basal nuclei showed such mRNA expression.

Discussion

Previously, Northern blot analysis showed that *LRRK2* is expressed in the cerebellum, cerebral cortex, medulla, spinal cord, occipital pole, frontal lobe, temporal lobe and putamen (Paisan-Ruiz *et al.*, 2004). However, a complete and detailed map of *LRRK2* mRNA localization in the central nervous system was still lacking. Thus, with the

© The Authors (2006). Journal Compilation © Federation of European Neuroscience Societies and Blackwell Publishing Ltd

objective of providing a complete atlas of the *LRRK2* mRNA distribution, we used *in situ* hybridization analysis with digoxigenin-labelled RNA probes on mice brain coronal sections. The results clearly show that *LRRK2* mRNA is distributed throughout the mouse brain. However, a stronger hybridization signal appears in specific brain regions such as the deep cerebral cortex layers, cingulate cortex, piriform cortex, Ammon's horn and dentate gyrus, caudate putamen, substantia nigra, some parts of the amygdala, reticular thalamic nucleus or cerebellar granular cell layer. Amongst these high *LRRK2* expression areas, the caudate putamen, the *substantia nigra pars compacta* and the granular cell layer of the cerebellum, are involved in the regulation of motor activity. As most clinical PD symptoms are related to motor dysfunction, this expression data may indicate a role of *LRRK2* in motor activity regulation. Regarding the appearance of *LRRK2* mRNA in the granular cell layer of the cerebellum, currently cerebellar symptoms have not been described in PD patients. Interestingly, several studies have related the appearance of parkinsonian motor features (parkinsonism) to the expansion of CAG repeats encoding polyglutamine tracts within spinocerebellar ataxia-related genes (Gwinn-Hardy *et al*., 2000; Wu *et al*., 2004; Simon-Sanchez *et al*., 2005). The phenotype of these spinocerebellar ataxia patients is variable and may cause a disease that clinically overlaps with Parkinson's disease.

Other structures indirectly related to motor activity regulation also express *LRRK2* mRNA. We detected strong hybridization signals in the hippocampus, piriform cortex, cingulate cortex, olfactory tubercle, amygdala or reticular thalamic nucleus. Potential relationships between these expression areas and PD pathology have been suggested by several groups studying PD and atrophy. Patients with demented PD showed grey matter volume decreases in several brain regions such as the putamen, accumbens nuclei, some parts of the thalamus, hippocampus or cingulate cortex (Summerfield *et al.,* 2005). Moreover, Camicioli *et al*. (2003) found that a hippocampus atrophy was more often displayed in PD patients than in healthy subjects regardless of any existing cognitive dysfunction. In relation to the amygdala, Junque *et al*. (2005) found that both demented and nondemented PD patients have clear amygdalar and hippocampal atrophies. As the amygdala and the hippocampus are key structures of the limbic system, *LRRK2* may play a role in this function. In this respect, it is interesting to note the absence of cognitive dysfunction in most PD patients with dardarin mutations (for example see Paisan-Ruiz *et al*., 2005).

As we have previously mentioned, we also found a strong *LRRK2* mRNA expression in the olfactory tubercle and some other olfactory related areas, such as the piriform cortex. It could be speculated from this finding that dardarin might play a role in the known loss of smell in idiopathic PD (Berendse *et al*., 2001).

One important finding from this work that may be relevant to the etiopathogenesis of PD, is the strong *LRRK2* expression in the putamen which contrasts with a lower or nonsignal in the globus pallidus. We can speculate that compensatory mechanisms between both areas might be disrupted as a consequence of dardarin dysfunction.

Wszolek and colleagues reported the finding of different pathological signatures in brain tissue from four members of a PD family with the R1441C dardarin mutation. These authors found Lewy body pathology in two of the four individuals. One of the two Lewy body positive patients also had tau inclusions. A third patient of this family had solely tau inclusions whereas a fourth one only showed neuronal loss and gliosis in the substantia nigra as found in the other three cases (Wszolek *et al*., 2004). Our results are consistent with this observations in that *LRRK2* is expressed in all the areas where Wszolek and colleagues found evidence of pathological lesions. Moreover, Gai *et al.* (2005) have recently reported the presence of dardarin in Lewy bodies, neurofibrillary tangles and dystrophic neurites in PD, diffuse Lewy body disease, Alzheimer's disease and Multiple System Atrophy suggesting that dardarin could be involved in mechanisms leading to neurodegeneration, at least within these disorders.

In summary, this study demonstrates the existence of *LRRK2* mRNA in many brain regions and nuclei. These results suggest that mutations in *LRRK2* could affect several motor structures that play an important role in PD development. In accord with this, most brain regions involved in the nigrostriatal pathway abundantly express *LRRK2* mRNA. The discovery of a strong *LRRK2* expression in structures such as the hippocampus, amygdala or olfactory tubercle, may indicate that *LRRK2* dysfunction leads to the appearance of the nonmotor symptoms that are characteristic of PD.

Acknowledgements

This work was supported by grants from the Ministerio de Educación y Ciencia (GEN2001-4851-C06-01) and Fundación Ramón Areces (DI-TER Parkinson) to JP-T. JS-S is a recipient of a CSIC fellowship (I3P) and VH-P is funded by a fellowship from the Ministerio de Sanidad y Consumo (BEFI). JP-T is part of a Generalitat Valenciana Network of Excellence (GRUPOS 2003/0015). The authors are greatly indebted to Ms Hellen Warburton and to Dr Jayanth Chandran for their assistance in editing this manuscript.

Abbreviations

APT, anterior pretectal nucleus; Arc, nucleus arcuatus; ASt, amygdalostriatal transition area; BLA, basolateral amygdala; BMA, basomedial amygdala; CA1, field 1 of the Ammon's horn; CA3, field 3 of the Ammon's horn; CeA, central amygdala; Cg, cingular cortex; ci, capsula interna; CoA, cortical amygdala; COR, C-terminal of Roc (domain); DG, dentate gyrus; DHA, dorsal hypothalamic area; dmVMH, dorsomedial division of the ventromedial hypothalamic nucleus; EW, edinger westfal nucleus; f, fornix; Fr, frontal cortex; GL, granular layer; GP, globus pallidum; HL, hindlimb cortex; ICj, islands of Calleja; IL, infralimbic medial prefrontal cortex; InG, intermediate grey layer of the superior colliculus; IP, interpeduncular nucleus; LA, lateral amygdala; lfp, longitudinal fasciculus of the pons; LHA, lateral hypothalamic area; LHb, lateral habenula; LL, lateral lemniscus; LOT, nucleus of the lateral olfactory tract; LRRK2, leucine-rich repeat kinase 2; MeA, medial amygdala; MGB, medial geniculate body; MHb, medial habenula; ot, optic tract; ML, molecular layer; PAG, periaqueductal grey; Par, parietal cortex; PD, Parkinson's disease; PFA, perifornical area; Pir, piriform cortex; PnN, pontine nuclei; Pu, putamen; PVP, paraventricular posterior thalamic nucleus; RN, red nucleus; Roc, Ras on complex proteins (domain); RPO, nucleus reticularis pontis oralis; RSG, retrosplenial granular cortex; RT, reticular thalamic nucleus; S, subiculum; SNC, substantia nigra pars compacta; SNR, substantia nigra pars reticulata; Te, temporal cortex; TT, tenia tecta; TuMC, tuberal magnocellular division of the lateral hypothalamic area; VEnd, ventral endopiriform division of the claustrum; vlVMH, ventralateral division of the ventromedial hypothalamic nucleus; VP, ventral pallidum; VPL, ventral posterolateral thalamic nucleus; WM, white matter; ZI, zona incerta.

References

Berendse, H.W., Booij, J., Francot, C.M., Bergmans, P.L., Hijman, R., Stoof, J.C. & Wolters E.C. (2001) Subclinical dopaminergic dysfunction in asymptomatic Parkinson's disease patients' relatives with a decreased sense of smell. *Neurology*, **50**, 34–41.

Bosgraaf, L. & Van Haastert, P.J. (2003) Roc, a Ras/GTPase domain in complex proteins. *Biochim. Biophys. Acta*, **1643**, 5–10.

Camicioli, R., Moore, M.M., Kinney, A., Corbridge, E., Glassberg, K. & Kaye, J.A. (2003) Parkinson's disease is associated with hippocampal atrophy. *Mov. Disord.*, **18**, 784–790.

Funayama, M., Hasegawa, K., Kowa, H., Saito, M., Tsuji, S. & Obata, F. (2002) A new locus for Parkinson's disease (PARK8) maps to chromosome 12p11. 2-Q13.1. *Ann. Neurol.*, **51**, 296–301.

© The Authors (2006). Journal Compilation © Federation of European Neuroscience Societies and Blackwell Publishing Ltd

Gai, W., Wu, C., Chilcote, T.J., Anderson, J.P., Schlossmacher, M.G., Blumbergs, P.C., Jensen, P. & Halliday, G.M. (2005) LRRK2 in neural inclusions in Parkinson's, Alzheimer's, and related diseases. *Soc. Neurosci. Abstr*., 1007.6.

Gwinn-Hardy, K., Chen, J.Y., Liu, H.C., Liu, T.Y., Boss, M., Seltzer, W., Adam, A., Singleton, A., Koroshetz, W., Waters, C., Hardy, J. & Farrer, M. (2000) Spinocerebellar ataxia type 2 with parkinsonism in ethnic Chinese. *Neurology*, **55**, 800–805.

Junque, C., Ramirez-Ruiz, B., Tolosa, E., Summerfield, C., Marti, M.J., Pastor, P., Gomez-Anson, B. & Mercader, J.M. (2005) Amygdalar and hippocampal MRI volume tric reductions in Parkinson's disease with dementia. *Mov. Disord.*, **20**, 540–544.

Paisan-Ruiz, C., Jain, S., Evans, E.W., Gilks, W.P., Simon, J., van der Brug, M., Lopez de Munain, A., Aparicio, S., Gil, A.M., Khan, N., Johnson, J., Martinez, J.R., Nicholl, D., Carrera, I.M., Pena, A.S., de Silva, R., Lees, A., Marti-Masso, J.F., Perez-Tur, J., Wood, N.W. & Singleton, A.B. (2004) Cloning of the gene containing mutations that cause PARK8-linked Parkinson's disease. *Neuron*, **44**, 595–600.

Paisan-Ruiz, C., Saenz, A., Lopez de Munain, A., Marti, I., Martinez Gil, A., Marti-Masso, J.F. & Perez-Tur, J. (2005) Familial Parkinson's disease: clinical and genetic analysis of four Basque families. *Ann. Neurol.*, **57**, 365–372.

Simon-Sanchez, J., Hanson, M., Singleton, A., Hernandez, D., McInerney, A., Nussbaum, R., Werner, J., Gallardo, M., Weiser, R., Gwinn-Hardy, K., Singleton, A.B. & Clarimon, J. (2005) Analysis of SCA-2 and SCA-3 repeats in Parkinsonism: evidence of SCA-2 expansion in a family with autosomal dominant Parkinson's disease. *Neurosci. Lett.*, **382**, 191–194.

Summerfield, C., Junque, C., Tolosa, E., Salgado-Pineda, P., Gomez-Anson, B., Marti, M.J., Pastor, P., Ramirez-Ruiz, B. & Mercader, J. (2005) Structural brain changes in Parkinson disease with dementia: a voxel-based morphometry study. *Arch. Neurol.*, **62**, 281–285.

Wszolek, Z.K., Pfeiffer, R.F., Tsuboi, Y., Uitti, R.J., McComb, R.D., Stoessl, A.J., Strongosky, A.J., Zimprich, A., Muller-Myhsok, B., Farrer, M.J., Gasser, T., Calne, D.B. & Dickson, D.W. (2004) Autosomal dominant parkinsonism associated with variable synuclein and tau pathology. *Neurology*, **62**, 1619–1622.

Wu, Y.R., Lin, H.Y., Chen, C.M., Gwinn-Hardy, K., Ro, L.S., Wang, Y.C., Li, S.H., Hwang, J.C., Fang, K., Hsieh-Li, H.M., Li, M.L., Tung, L.C., Su, M.T., Lu, K.T. & Lee-Chen, G.J. (2004) Genetic testing in spinocerebellar ataxia in Taiwan: expansions of trinucleotide repeats in SCA8 and SCA17 are associated with typical Parkinson's disease. *Clin. Genet.*, **65**, 209–214.

© The Authors (2006). Journal Compilation © Federation of European Neuroscience Societies and Blackwell Publishing Ltd